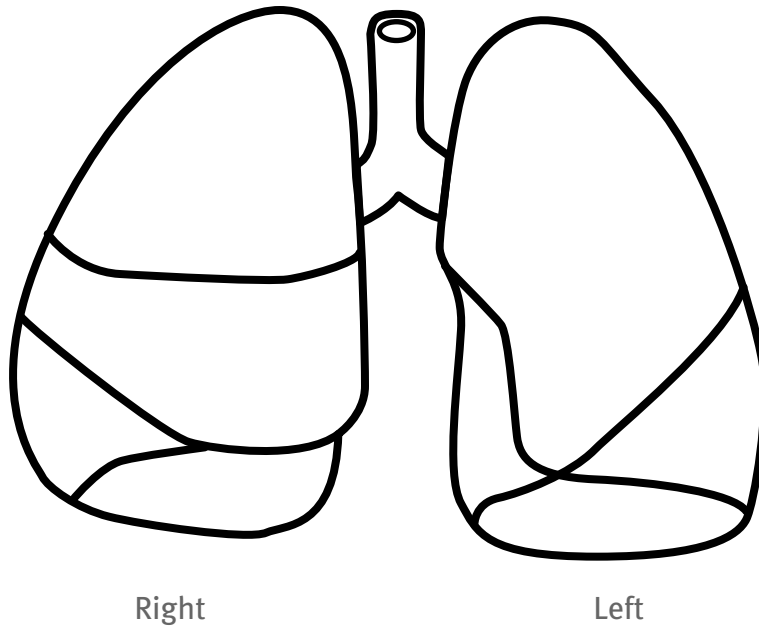


Lungs

The diagrams below depict images of the lungs. Draw or make note of abnormalities or other findings on the appropriate diagram.

Intact,
front view



Cross-section,
front view

